



2018

GPS for the GP: Guided Planning Surgery

Benjamin E. Schwartz

Touro College of Dental Medicine at NYMC, benjamin.schwartz11@touro.edu

Follow this and additional works at: https://touro scholar.touro.edu/cdm_pubs



Part of the [Dentistry Commons](#)

Recommended Citation

Schwartz, B. E. (2018, Spring). GPS for the GP: Guided planning surgery. *Journal of the New York State Academy of General Dentistry*, 12-13.

This Article is brought to you for free and open access by the Touro College of Dental Medicine at NYMC at Touro Scholar. It has been accepted for inclusion in Touro College of Dental Medicine Publications and Research by an authorized administrator of Touro Scholar. For more information, please contact touro.scholar@touro.edu.

GPS for the GP: Guided Planning Surgery

By Benjamin Schwartz, DDS, FAGD, FICOI

We all know the feeling; you're about to perform dental implant surgery, and while you're excited at the opportunity, you are also nervous. What if your osteotomy is angled wrong? What if you place the implant too close to an adjacent tooth? Will you really be able to get those implants parallel?

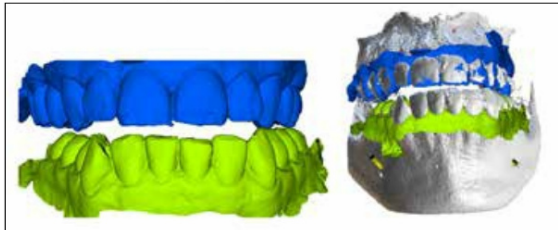


Figure 1. STL models of the arches and their alignment to the DICOM data.

It is imperative that the implant be placed in an ideal location for the final restoration. The concept of a crown-down technique has been applied to implant dentistry, so that the implant should be placed where the tooth will eventually go, and not the reverse. This allows for better long-term success of the implant while simultaneously keeping prosthetic component costs to a minimum.

Guided planning surgery (GPS) programs are a valuable tool for the general dentist to help direct the proper implant orientation in order to prevent errors during the surgical procedure. Software exists that can plan implant and restorative tooth positions, auto-detect nerves, warn of proximity to vital structures, caution against incorrect implant locations, and fabricate surgical guides. Some examples of different GPS systems are Invivo 5 (Anatomage), Implant Studio (3 Shape), and Simplant (Dentsply Sirona). In addition, many CBCT programs come bundled with their own implant planning program that can be used to plan implant positions and create surgical guides. While most of these systems have similar capabilities and functions, variations exist regarding ease of use, open vs closed platforms, compatibility with all major implant brands, their accuracy, and ability to design all types of cases.

The inherent problem with most guided implant systems is the prohibitive cost of the necessary elements. Implant surgical guides can vary in cost from \$200-\$3,500, while a guided surgery kit alone can cost more than \$1,500! One system that I have found very versatile and robust, with low costs and great accuracy is BlueSky Plan (BlueSky Bio). The program is free to download and use, and has nominal costs to export surgical guides. The system can be used to fabricate tooth borne, mucosa borne, and even bone borne implant guides.

While all practitioners should learn more about guided implant surgery, bear in mind that one must have the ability to place the implant non-guided as well. Referred to as 'brain-guided', one must understand the intricacies of dental implant surgery before attempting any procedure.

Below are cases that were planned and carried out using a GPS approach.

Jim, a 40-year-old male patient, presented to our office seeking to replace his missing posterior teeth. After a thorough examination

www.nysagd.org | Spring 2018 | GP 12

and discussion, the patient opted to have dental implants placed. A CBCT image was taken and the DICOM (Digital Imaging and Communications in Medicine) data was imported into the GPS BlueSky Plan software. The inferior alveolar nerve was mapped using the auto-detect nerve feature and verified. Stereolithography (STL) models of the intraoral scans were imported and aligned (Figure 1), the relative tooth positions were planned, and implants were then virtually placed based on bone morphology and future tooth alignment using the GPS software. This allows the implants to be planned with the final tooth position in mind. Dental implant surgical guides were designed and an STL of the guides was exported. The surgical guides were then produced with a 3-D printer. After cleanup, guide tube sleeve inserts were placed, and the guides were cold sterilized prior to the surgical procedure (Figure 2). When Jim arrived, full thickness flaps were reflected, the tooth

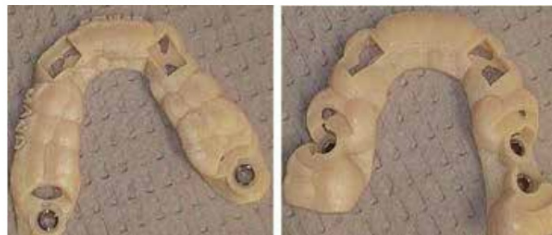

Figure 2. Maxillary and mandibular surgical guides.

borne guides were seated, and implant osteotomies were created through the guides. The implants were placed with very good primary stability. Healing abutments were placed, and the flaps were sutured around them to allow for an easier transition to the final crown. As can be seen from the radiograph (Figure 3), align-

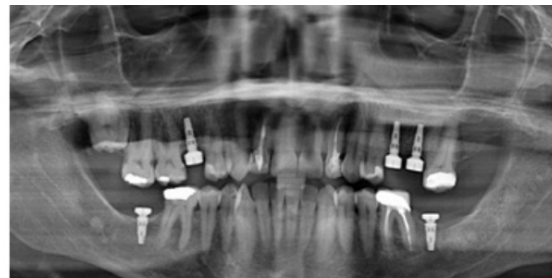

Figure 3. Post-operative panoramic radiograph.

ment and positions were exactly as planned (Figure 4), and the final prosthetic result should allow for screw-retained restorations. Utilizing the GPS software, the entire procedure took less than an

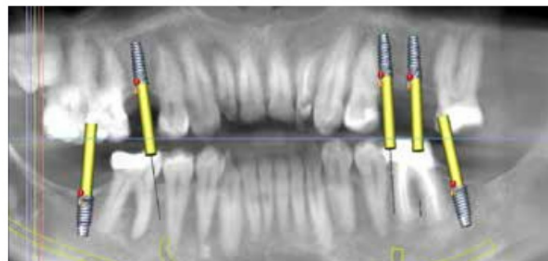


Figure 4. Planned implant placement via BlueSky Plan.

hour, and did not induce any unnecessary perspiration on behalf of the practitioner.

This next case involves the conversion of a denture to an implant-supported overdenture. These can be very traumatic as there is often a need for full flap reflection to visualize the nerve. However, utilizing the latest in dental technology, we were able to perform this case quickly, relatively painlessly, and very inexpensively.

Martin, a 68-year-old male presented to our office with a pre-existing complete lower denture. He stated that he dislikes his lower denture since it moves when he ate and wished to have dental implants placed to help make it more secure. After a thorough medical and intra-oral examination, including a CBCT and verifying the fit of his current prosthesis, we elected to convert his existing denture to

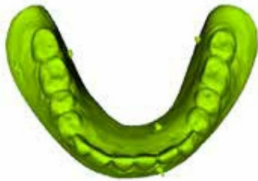

Figure 5. Virtual denture duplicate with radio-graphic markers present.

an implant-supported overdenture. Radiographic markers were placed on his denture, and they were scanned in a cone beam machine, thus creating a DICOM format that can be converted within the GPS BlueSky Plan software to an STL format (Figure 5). Once we aligned the STL to the edentulous DICOM data, we were then able to plan our implants. Still utilizing this same virtual denture duplicate, a mucosa based surgical guide was created (Figure 6) following the contour of his current denture. The implant osteot-

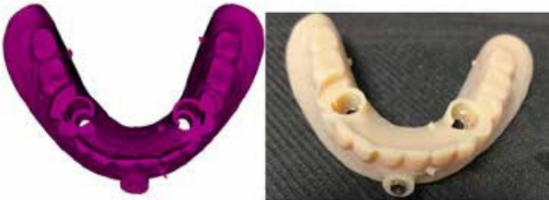

Figure 6. Tissue borne surgical guide based on denture.

omies were then created through the guide, and the implants were placed exactly as planned (Figure 7). Post-op discomfort was minimal, and Martin was thrilled with his new and improved denture!

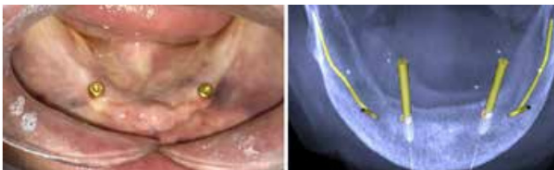

Figure 7. Mandibular implants with over-denture attachments.

Now let's break down the costs of these procedures: STL export of a surgical guide = \$20, single guide tube = \$7, printing of guide (if utilizing an outsourced printer) = \$43, which brings an average total case cost to \$70. For Jim's case, which involved two surgical guides and five guide tubes using an outsourced printing source, our upfront cost to fabricate the guides was \$141. While in Martin's case, where only two guide tubes were used, the total cost was a nominal \$77. By using BlueSky Plan, our initial costs to utilize computer guided surgery was relatively low compared to what other GPS programs and 3D design services would cost.

Guided planning surgery allows for a comprehensively planned dental implant procedure with great accuracy. Using a GPS based approach, your treatment time is usually faster, less invasive, and often allows for better implant placement. This translates into a better experience for both you and the patient alike.



Dr. Benjamin Schwartz maintains private practices in New York City and Long Island and is an Assistant Professor at Touro College of Dental Medicine. He is a Fellow in the Academy of General Dentistry and a Fellow of the International Congress of Oral Implantologists.

NYU ORAL CANCER
WALK
NEW YORK CITY
advocacy | education | prevention

This year's NYU Oral Cancer Walk will take place on Sunday, April 29th. The walk will start from the David B. Kriser Dental Center at 345 East 24th Street. Check-in opens at 9am with opening ceremonies to begin at 10am. The goals of the annual walk are to raise awareness of oral cancer, to sensitize the community to seek early care, and to support oral cancer research.

As in the past, the New York State AGD has been an active supporter of this event and encourages you to take part in this worthy cause. All proceeds from the walk will go directly to the NYUCD Oral Cancer Research Center and will enable them to continue the fight against oral cancer. You can do your part by either making a donation or participating in the walk. The link to the registration / donation site is not completed at this time. When registering or donating, please be sure to join "Team New York AGD."

www.nysagd.org | Spring 2018 | GP 13