

1-1-2016

## Minimally Invasive Surgery in Pediatric Trauma: One Institution's 20-Year Experience

Gustavo Stringel  
*New York Medical College*

Min Li Xu

Joseph Lopez

Follow this and additional works at: [https://touro scholar.touro.edu/nymc\\_fac\\_pubs](https://touro scholar.touro.edu/nymc_fac_pubs)



Part of the [Pediatrics Commons](#), and the [Surgery Commons](#)

---

### Recommended Citation

Stringel, G., Xu, M. L., & Lopez, J. (2016). Minimally invasive surgery in pediatric trauma: One institution's 20-year experience. *JSLS : Journal of the Society of Laparoendoscopic Surgeons*, 20(1), e2015.00111. doi:10.4293/JSLS.2015.00111

This Article is brought to you for free and open access by the Faculty at Touro Scholar. It has been accepted for inclusion in NYMC Faculty Publications by an authorized administrator of Touro Scholar. For more information, please contact [touro.scholar@touro.edu](mailto:touro.scholar@touro.edu).

# Minimally Invasive Surgery in Pediatric Trauma: One Institution's 20-Year Experience

Gustavo Stringel, MD, MBA, Min Li Xu, MD, Joseph Lopez, MD

## ABSTRACT

**Background:** Minimally invasive surgery (MIS) for trauma in pediatric cases remains controversial. Recent studies have shown the validity of using minimally invasive techniques to decrease the rate of negative and non-therapeutic laparotomy and thoracotomy. The purpose of this study was to evaluate the diagnostic accuracy and therapeutic options of MIS in pediatric trauma at a level I pediatric trauma center.

**Methods:** We reviewed cases of patients aged 15 years and younger who had undergone laparoscopy or thoracoscopy for trauma in our institution over the past 20 years. Each case was evaluated for mechanism of injury, computed tomographic (CT) scan findings, operative management, and patient outcomes.

**Results:** There were 23 patients in the study (16 boys and 7 girls). Twenty-one had undergone diagnostic laparoscopy and 2 had had diagnostic thoracoscopy. In 16, there were positive findings in diagnostic laparoscopy. Laparoscopic therapeutic interventions were performed in 6 patients; the remaining 10 required conversion to laparotomy. Both patients who underwent diagnostic thoracoscopy had positive findings. One had a thoracoscopic repair, and the other underwent conversion to thoracotomy. There were 5 negative diagnostic laparoscopies. There was no mortality among the 23 patients.

**Conclusions:** The use of laparoscopy and thoracoscopy in pediatric trauma helps to reduce unnecessary laparotomy and thoracotomy. Some injuries can be repaired by a minimally invasive approach. When conversion is necessary, the use of these techniques can guide the placement and size of surgical incisions. The

goal is to shift the paradigm in favor of using MIS in the treatment of pediatric trauma as the first-choice modality in stable patients.

**Key Words:** Laparoscopy, Minimally invasive surgery, Pediatric surgery, Thoracoscopy, Trauma.

## INTRODUCTION

Laparoscopic and thoracoscopic surgery have gradually become an accepted diagnostic and therapeutic modality in the treatment of pediatric trauma.<sup>1-5</sup> In the hands of experienced surgeons and in appropriate situations, minimally invasive surgery (MIS) has helped to eliminate the need for open procedures.<sup>6-14</sup> Physical examination can often be challenging and unreliable in the pediatric population. In children with equivocal laboratory or imaging findings, laparoscopy and thoracoscopy are better methods for establishing a diagnosis without the sequela of open surgery. One of the advantages of MIS is that it avoids extensive open procedures that produce negative findings or identify injuries that do not require repair (nontherapeutic). More important, MIS leads to less pain, quicker recovery time, shorter hospital stays, and decreased financial burden.<sup>3,5,10,11,13,14</sup> The purpose of this study was to review our institution's experience in using MIS as a first-choice modality in managing cases of pediatric trauma over the past 2 decades.

## MATERIALS AND METHODS

A retrospective study reviewing the past 20 years was performed at the Maria Fareri Children's Hospital of Westchester Medical Center, a tertiary care center with an American College of Surgeons level 1 pediatric trauma designation. After institutional review board approval was obtained, a list was compiled of all pediatric patients (age range, 0–15 years) who had sustained traumatic abdominal or thoracic injuries that required intervention. All patients in this study underwent diagnostic laparoscopy or thoracoscopy. Patients who required immediate open operations were excluded from the study. Data included the age and sex of the patient, type and mechanism of injury,

New York Medical College, Valhalla, New York (all authors).

Westchester Medical Center and Maria Fareri Children's Hospital, Valhalla, New York (Dr Stringel).

Address correspondence to: Gustavo Stringel, MD, 21 Addison Street, Larchmont, New York 10538. Telephone: 914-471-2444, Fax: 914-594-2321, E-mail: gstringel@aol.com

DOI: 10.4293/JSLS.2015.00111

© 2016 by JSLS, Journal of the Society of Laparoendoscopic Surgeons. Published by the Society of Laparoendoscopic Surgeons, Inc.

initial laboratory and imaging findings, and method of intervention (MIS vs open).

### Surgical Technique

All procedures were performed in patients under general anesthesia. The peritoneal cavity was accessed via an infraumbilical port. In cases of abdominal stab wounds, one of the wounds was used for initial port entry.

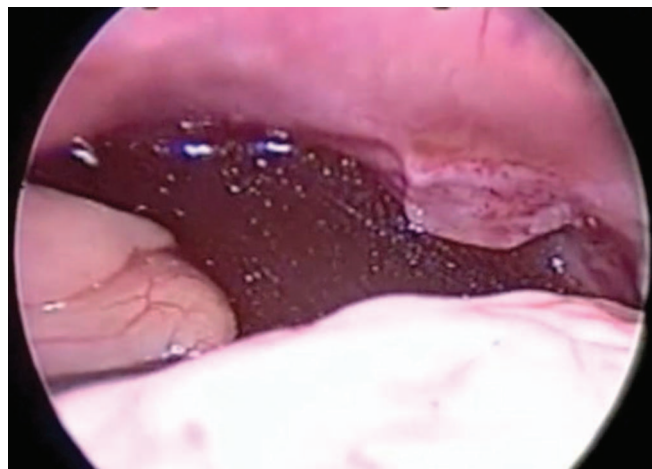
In patients with prior abdominal or laparoscopic surgery, we recommend a visual trocar with left upper quadrant entry. Two 5-mm ports are placed in the left lower quadrant. This position generally allows for total inspection of the peritoneal cavity. A fourth 5-mm port can be placed in the right side of the abdomen, if necessary. A careful systematic examination of the whole abdominal cavity is conducted. The liver and spleen are carefully inspected, and the stomach, duodenum, and diaphragms are evaluated. The lesser sac is opened to rule out pancreatic injury. The whole intestine is inspected, from the ligament of Treitz to the ileocecal valve, including the colon and rectum. Retroperitoneal hematomas are observed for expansion but are not opened or explored. It is important to evaluate the mesentery to rule out bleeding or mesenteric tear, which can cause internal hernia. Blood and clots must be evacuated, to facilitate a thorough evaluation of some of the involved areas.

The surgeon must be aware that some areas, such as the third and fourth portions of the duodenum, the pancreas, and the retroperitoneum, are difficult to evaluate. Further imaging may complement the laparoscopic examination.

### RESULTS

Twenty-three patients were treated by MIS at the Maria Fareri Children's Hospital between 1994 and 2014. There were 17 boys and 6 girls (mean age,  $9.3 \pm 4.47$  years). Most injuries (69.5%) occurred in children in grade school and beyond. The majority of the injuries (78%) were caused by blunt mechanisms; there were 5 (22%) penetrating injuries. These frequencies are a reflection of the type of trauma that occurs in our catchment area. All patients, with the exception of those with stab wound trauma, underwent radiological imaging before they were taken to the operating room. Positive findings on computed tomographic (CT) scans included hemoperitoneum (**Figure 1**) or pneumoperitoneum, active extravasation of contrast, and the presence of free fluid.

Twenty-one patients underwent diagnostic laparoscopy and 2 patients had diagnostic thoracoscopy; 16 of 21

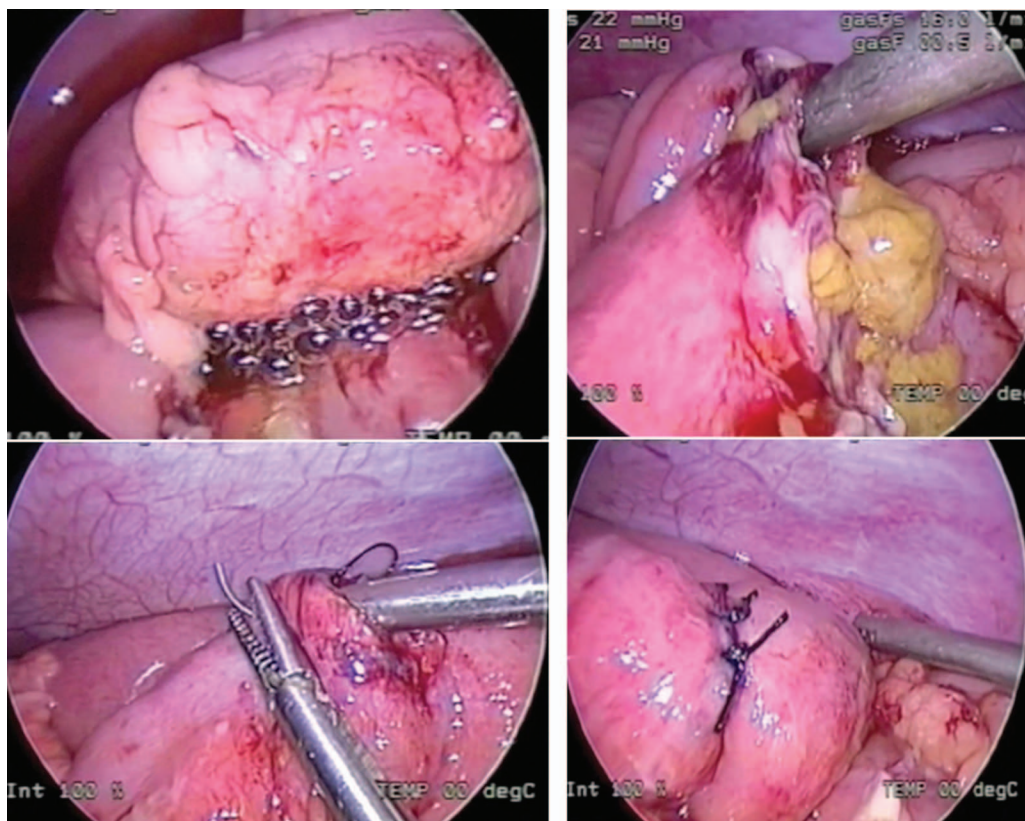


**Figure 1.** Hemoperitoneum.

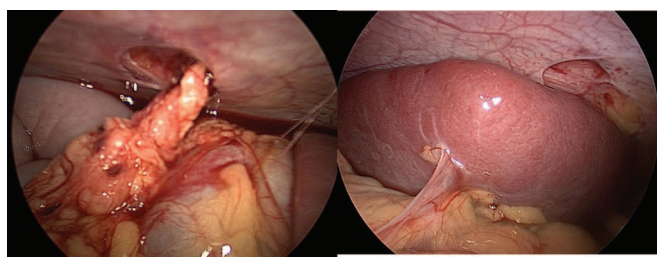
(76%) diagnostic laparoscopies and 2 of 2 (100%) diagnostic thorascopies had positive findings. The various types of injuries included bowel perforation (**Figure 2**), abdominal wall defect, diaphragmatic laceration, intra-abdominal hematoma, mesenteric tear, lung laceration, and pancreatic injury. After positive findings on diagnostic laparoscopy, 6 (37.5%) patients had laparoscopic repair, and the remaining 10 (62.5%) underwent conversion to open repair. After diagnostic thoracoscopy ( $n = 2$ ), 1 patient underwent thoracoscopic repair, and 1 had conversion to open repair. Laparoscopic and thoracoscopic repairs were performed on bowel perforations and diaphragmatic and pancreatic injuries. Open repairs were also performed on bowel perforations, mesenteric tears, and abdominal wall defects detected on diagnostic laparoscopy (**Figure 3**). All results are summarized in **Table 1**.

Among the 5 negative diagnostic laparoscopies, there was 1 missed injury during the initial laparoscopy. The patient was a 12-year-old boy who was involved in a bicycle accident with a handlebar injury and was found to have a hemoperitoneum in the subhepatic and paracolic gutters on CT scan. After a negative diagnostic laparoscopy, the patient continued to have abdominal pain. A follow-up upper gastrointestinal (GI) series demonstrated contrast leak in the third portion of the duodenum. The patient underwent exploratory laparotomy and an omental patch repair of the duodenal perforation. The duodenal injury was suspected during laparoscopy; a decision was made not to convert to laparotomy but to continue careful observation and further imaging if clinically indicated.

The length of stay in the hospital ranged from 1 to 55 days (mean,  $12.8 \text{ d} \pm 15.1$ ). There was no mortality among the 23 patients. After discharge from the hospi-



**Figure 2.** Top left: bubbles from an intestinal perforation. Top right: large intestinal perforation with soiling. Bottom: laparoscopic repair



**Figure 3.** Stab wound with eviscerated omentum, just missing the spleen.

tal, follow-up outpatient visits were scheduled from 2 weeks up to 1 year. Most of the patients recovered without complication.

Three complications were identified during the follow-up visits. A 13-month-old girl who was the victim of child abuse sustained a transection of the pancreatic tail. She was initially treated conservatively with abdominal wash-out and drain placement. However, over the next few months, the patient had persistent pancreatitis. At 10 months after the surgery, the patient was brought back to

the hospital for a laparoscopic distal pancreatectomy. In our institution, the initial management of pancreatic injuries is conservative, unless the patient is clinically unstable. We continue careful follow-up for possible complications. In this case, persistent pancreatitis was successfully managed with laparoscopic distal pancreatectomy with excellent outcome.

Another case involved a 9-year-old boy who underwent conversion to open repair for a jejunal perforation and developed a wound infection at the incision site 2 weeks after the operation. The wound was opened and allowed to heal by secondary intention.

Last, a 5-year-old boy who sustained severe rectal injuries had perineal and rectal laceration with avulsion of the rectum and anus off of the pelvis. The patient underwent diagnostic laparoscopy, and there were no identified intraperitoneal injuries. Because of the severity of his injury, he was treated with a transverse colostomy. At his 3-month follow-up, severe stenosis of the rectum was noted.



**Table 1.**  
Results of the Case Review

Parameter	Cases (n)	
Age (years)		
Infant (0–1)	1	
Pre-school (2–5)	6	
Grade school (6–12)	9	
Teenager (13–15)	7	
Type of trauma		
Blunt	18	
Penetrating	5	
Mechanism of injury		
Motor vehicle accident	7	
Bicycle accident	3	
Impaled by foreign body	3	
Stab wound	2	
Child abuse	2	
Swallowed foreign body	2	
Sports injury	2	
Pedestrian vs vehicle accident	1	
Result of diagnostic laparoscopy		
Positive	2	
Laparoscopic repair	1	
Open repair	1	
Negative	0	
Result of diagnostic thoracoscopy		
Positive	2	
Thoracoscopic repair	1	
Open repair	1	
Negative	0	
Type of internal injury		
Bowel perforation	9	
Abdominal wall defect	3	
Diaphragmatic laceration	2	
Intra-abdominal hematoma	2	
Mesenteric tear	2	
Lung laceration	1	
Pancreatic injury	1	
Type of repair (n)	Laparoscopic	Open
Repair of bowel perforation	4	5
Diaphragmatic repair	1	1
Mesenteric tear repair	0	2
Abdominal wall defect (hernia) repair	0	3
Pancreatic injury repair	1	0
N = 23.		

## DISCUSSION

The paradigm for treatment of pediatric trauma is rapidly changing, as surgeons become more comfortable and competent in minimally invasive surgery.<sup>3,5,6,12,14</sup> Our institution's experience over the past 20 years parallels the current literature in pediatric trauma. Laparoscopic surgery in pediatric abdominal trauma has been shown to reduce negative and nontherapeutic laparotomy rates by 40% to 60%.<sup>2–8</sup> In our study, 4 of 21 (19%) negative laparoscopies did not require any intervention. One of the most common fears about the use of MIS in pediatric trauma is the possibility of missing an injury that might have been found by laparotomy. However, the current literature has estimated missed injuries by diagnostic laparoscopy to be close to 0% in pediatric trauma.<sup>2–3,7,9</sup> Of the 21 diagnostic laparoscopies for trauma performed at our institution, we had 1 missed duodenal perforation on initial laparoscopy. The injury was identified on a postoperative upper GI series and repaired by laparotomy. Although the duodenal injury was missed during laparoscopy, visualization of the duodenum raised enough suspicion of the injury to warrant careful follow-up and further imaging to exclude a duodenal injury. The outcome in this patient was excellent, and other injuries were excluded by laparoscopy.

In addition to its diagnostic capabilities, MIS therapeutic interventions are possible in up to 65% of cases without conversion to an open procedure.<sup>7</sup> Definitive repair using only MIS techniques was achieved in 38.8% of our cases of abdominal and thoracic traumatic injury.

The management of solid-organ injury in pediatric patients continues to be mainly nonoperative.

The average length of hospital stay of our trauma patients was under 2 weeks. Patients who were underwent MIS repair stayed in the hospital for a mean of  $7 \pm 1.9$  days. For patients who required open repair, the average duration of hospitalization was  $15 \pm 15.1$  days. The difference in hospital stay between the two groups was not statistically significant ( $P = .18$ ), most likely because of the great variability among our patients. Patients who needed open repair may have presented with more critical injuries and hemodynamic instability. Length of hospitalization also depended on coexisting severe injuries that required prolonged care.

## CONCLUSIONS

The use of laparoscopy and thoracoscopy in pediatric trauma can avoid unnecessary laparotomy and thoracotomy. Some of the injuries encountered can be re-

paired by a minimally invasive approach. If conversion is necessary, the use of these techniques can guide the placement and size of surgical incisions. We recommend that laparoscopy and thoracoscopy be the primary intervention in hemodynamically stable pediatric patients with traumatic injury, when clinically indicated.

## References:

1. Gandhi RR, Stringel G. Laparoscopy in pediatric abdominal trauma. *JSLS*. 1997;1:349–351.
2. Feliz A, Shultz B, McKenna C, Gaines BA. Diagnostic and therapeutic laparoscopy in pediatric abdominal trauma. *J Pediatr Surg*. 2006;41:72–77.
3. Streck CJ, Lobe TE, Pietsch JB, Lovvorn HN 3rd. Laparoscopic repair of traumatic bowel injury in children. *J Pediatr Surg*. 2006;41:1864–1869.
4. Marwan A, Harmon CM, Georgeson KE, Smith GF, Muensterer OJ. Use of laparoscopy in the management of pediatric abdominal trauma. *J Trauma*. 2010;69:761–764.
5. Sharp NE, Holcomb GW 3rd. The role of minimally invasive surgery in pediatric trauma: a collective review. *Pediatr Surg Int*. 2013;29:1013–1018.
6. Gaines BA, Rutkoski JD. The role of laparoscopy in pediatric trauma. *Semin Pediatr Surg*. 2010;19:300–303.
7. Alemayehu H, Clifton M, Santore M, et al. Minimally invasive surgery for pediatric trauma: a multicenter review. *J Laparoendosc Adv Surg Tech A*. 2015;25:243–247.
8. O'Malley E, Boyle E, O'Callaghan A, Coffey JC, Walsh SR. Role of laparoscopy in penetrating abdominal trauma: a systematic review. *World J Surg*. 2013;37:113–122.
9. Ransom KJ, Smith S. Laparoscopy for trauma. In: Wetter PA, Kavic SM, Levinson CJ, eds. *Prevention and Management of Laparoendoscopic Complications*, 3rd edition. Miami, FL: Society of Laparoendoscopic Surgeons; 2012:Chapter 38.
10. Chestovich PJ, Browder TD, Morrissey SL, Fraser DR, Ingalls NK, Fildes JJ. Minimally invasive is maximally effective: diagnostic and therapeutic laparoscopy for penetrating abdominal injuries. *J Trauma Acute Care Surg*. 2015;78:1076–1085.
11. Kaban GK, Novitsky YW, Perugini RA, et al. Use of laparoscopy in evaluation and treatment of penetrating and blunt abdominal injuries. *Surg Innov*. 2008;15:26–31.
12. Fuentes S, Cano I, Lopez M, et al. Laparoscopia como método diagnóstico-terapéutico en el traumatismo abdominal en la edad pediátrica. [Laparoscopy as diagnostic-therapeutic method in abdominal trauma in the pediatric age group (abstract published in English and Spanish)]. *Cir Pediatr*. 2011;24:115–117.
13. Marks JM, Youngelman DF, Berk T. Cost analysis of diagnostic laparoscopy vs laparotomy in the evaluation of penetrating abdominal trauma. *Surg Endosc*. 1997;11:272–278.
14. Taner AS, Topgul K, Kucukel F, Demir A, Sari S. Diagnostic laparoscopy decreases the rate of unnecessary laparotomies and reduces hospital costs in trauma patients. *J Laparoendosc Adv Surg Tech*. 2001;11:207–211.